Session 11: Hallux Rigidus and Hallux Valgus

Co-Moderators: Craig Payne, B. Pod (La Trobe University) and Don Anderson, PhD (University of Iowa)

3:00PM *11-1:* Netto, Cesar de Cesar, et al. First Tarsometatarsal Joint Shape and Orientation: Can We Trust in Our Radiographic Findings?

3:10PM *11-2:* Dunbar, Julia L., et al. Great Toe Adduction Decreases Blood Flow to Plantar Fascia: A Pilot Study

3:20PM *11-3:* Hillstrom, Rajshree, et al. Effect of Plantar Fascia Stiffness upon First Metatarsophalangeal Joint Stress – A Biphasic Finite Element Study

3:30PM *11-4:* Morgan, Oliver, et al. Cheilectomy and Moberg Osteotomy: A Biphasic Prediction of First Metatarsophalangeal Joint Stress

3:40PM *11-5:* Kimura, Tadashi, et al. Evaluation of joint mobility around the cuneiform between hallux valgus & normal feet using 3D analysis system & weight-bearing CT

3:50PM *11-6:* Volpert, Lauren G., et al. Comparing First Metatarsophalangeal Joint Flexibility Measurements in Hallux Rigidus Patients Pre- and Post-Cheilectomy Using a Novel Flexibility Device

Session 11-1

First Tarsometatarsal Joint Shape and Orientation: Can We Trust in Our Radiographic Findings?

Cesar de Cesar Netto[1]; Lauren Roberts[1]; Guilherme Honda Saito[1]; Scott Ellis[1]; Ashish Shah[2]
[1]Hospital for Special Surgery, NY, [2]University of Alabama at Birmingham

NOTHING TO DISCLOSE

INTRODUCTION

Studies have demonstrated that patients with hallux valgus (HV) deformities have increased mobility in the first tarsometatarsal (TMT) joint. Anatomical factors widely considered to play a role in the instability are shape and frontal plane orientation of the joint. An oblique rather than horizontal orientation of the articular surfaces and a round shape, rather than a flat shape, are believed to predispose to the deformity. The purpose of this study was to assess whether the shape and angulation of the first TMT joint are affected by the positioning of the foot and orientation of the x-ray beam.

METHODS

Ten adult above knee fresh frozen cadaveric specimens were used, with a mean age of 79.9 (range, 54-88) years. There were no clinical forefoot deformities noted in any of the feet. One of the specimens had moderate ankle arthritis and one had a mild cavus-varus. A radiolucent loading apparatus was built that, allowing neutral positioning of a plantigrade foot and controlled angulation of 5°, 10°, 15° and 20° in dorsiflexion, plantarflexion, inversion and eversion. Fluoroscopic images were obtained of each cadaveric specimen in all seventeen different positions, with the x-ray beam perpendicular to the floor and aiming to the base of the 1st metatarsal. Two blinded orthopaedic surgeons independently measured the 1st tarsometatarsal (TMT) joint angle, where values above 90° represented increased valgus or abduction alignment of the 1st TMT and graded the distal articular cartilage of the medial cuneiform as flat or curved. Readers also graded the image quality into assessing the joint into "Low", "Intermediate" and "Good".

RESULTS

The mean value for 1st TMT joint angle was 112.92° ± 6.89°. Values were significantly different between the cadaveric specimens ($p<.0001$) and ranged from 96.7° to 129.98°. There was a tendency for increased valgus angulation of the joint in images positioned in neutral, plantarflexion and inversion and decreased valgus angulation with dorsiflexion and eversion.

Regarding the shape of the distal articular cartilage of the medial cuneiform, joints with flat configuration showed significantly increased mean 1st TMT joint angle when compared to curved surfaces (115.9° vs. 110.7°, $p<.0001$). There was also a tendency for flattening of the joint in images positioned in dorsiflexion and inversion.

In 8 out of 10 of the cadaveric specimens (80%) the shape of the 1st TMT joint changed between curved or flat configuration depending on the positioning of the foot. In only 2/10 (20%) the joint configuration remained the same for all different positions (one flat and one curved)

Image quality for visualization of the 1st TMT joint was progressively better for increased angles of dorsiflexion and inversion and progressively worse for plantarflexion and eversion.

CONCLUSION

Our cadaveric study found that the shape and angulation of the first TMT joint is affected by the positioning of the foot and orientation of the x-ray beam.

CLINICAL RELEVANCE: Clinical usefulness of the 1st TMT radiographic anatomical characteristics is limited and should not influence in the treatment of patients with possible instability the first tarsometatarsal (TMT) joint.

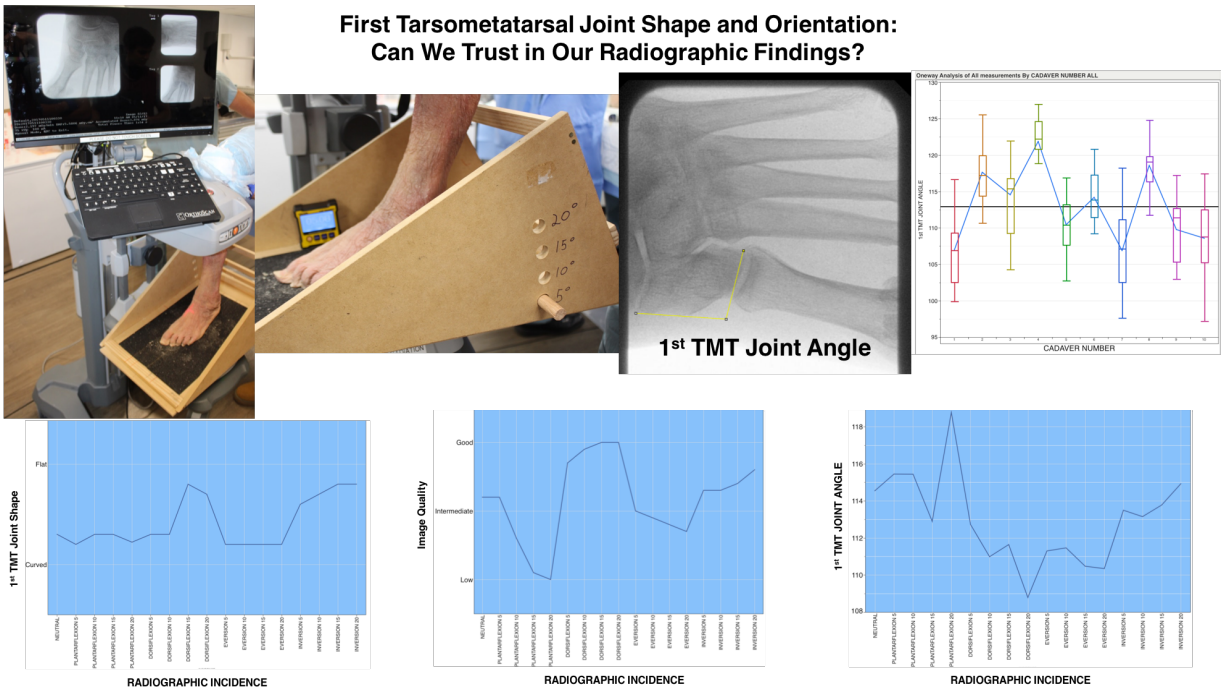

Great Toe Adduction Decreases Blood Flow to Plantar Fascia: A Pilot Study

Julia L. Dunbar[1], Daniel M. Hoopes[2], Sarah T. Ridge[1], Dustin A. Bruening[1], A. Wayne Johnson[1]
[1]Brigham Young University, Provo, UT, [2]Revere Health Orthopedics, Provo, UT
Email of Presenting Author: juliadunbar4@gmail.com

Disclosures: Julia L. Dunbar (N), Daniel M. Hoopes (N), Sarah T. Ridge (N), Dustin A. Bruening (N), A. Wayne Johnson (N)

INTRODUCTION: Plantar fasciitis has been reported to be the most common foot condition diagnosed by medical professionals. However, in spite of its prevalence, the cause of plantar fasciitis remains unclear. Most researchers agree that the etiology is multifactorial with mechanical and physiological components, but further investigation of the development of plantar fasciitis is needed in order to help clinicians develop effective treatment plans. The plantar fascia, along with several intrinsic foot muscles, receives blood supply from the medial and lateral plantar arteries. Physicians have theorized that an adducted great toe, as seen inside a narrow shoe, may put passive tension on the abductor hallucis. Since the medial and lateral plantar arteries run deep to the abductor hallucis between the muscle and the calcaneus, tensing of this muscle may put pressure on the plantar arteries, decreasing blood flow to the plantar fascia. The purpose of this study was to compare blood flow within the lateral plantar artery before and after passive great toe adduction.

METHODS: Ten subjects (5 male, 5 female, age: 29.2 ± 10.0 years, height: 177.5 ± 9.1 cm, weight: 74.8 ± 17.2 kg) volunteered to participate in this IRB approved study. Subjects were healthy and free of lower extremity injury. Blood flow was measured using pulse-wave ultrasound imaging (ML6-15 probe, GE Logiq S8). Subjects were seated with the ankle in 30° plantar flexion. The lateral plantar artery was imaged just deep to the abductor hallucis. Blood flow was first measured with the great toe in a resting neutral position. The great toe was then passively adducted with moderate pressure enough to cause visible tensing of the muscle, and blood flow was measured again. The diameter of the vessel was measured from the images, and the rate of blood flow was then calculated using the internal software of the ultrasound machine.

RESULTS: A paired t-test indicated the rate of blood flow was significantly lower post-adduction compared to the pre-adduction condition (Pre: 1.51 ± 0.76 ml/min, Post: 0.88 ± 0.61 ml/min, $p=0.001$) (Figure 1). There was a 42% decrease in the rate of blood flow after passive adduction.

DISCUSSION: Based on this preliminary data, it appears that passive adduction of the great toe may decrease the rate of blood flow within the plantar arteries. This decrease in blood flow is likely due to the tensed abductor hallucis putting pressure on the vessels. However, seeing as there were only ten subjects and was no control condition, further investigation is needed to confirm these findings. Diminished blood flow in combination with mechanical stress on the plantar fascia could lead to poor healing and contribute to the development of plantar fasciitis. Future research will aim to determine the effect of footwear on great toe position and plantar artery blood flow in order to draw conclusions of clinical significance.

SIGNIFICANCE/CLINICAL RELEVANCE: The results of this pilot study suggest there may be a relationship between an adducted great toe position and decreased blood flow to the plantar fascia. This decrease in blood flow, if prolonged, could ultimately result in the development of plantar fasciitis or the prevention of its healing.

FIGURES AND TABLES:

Figure 1:

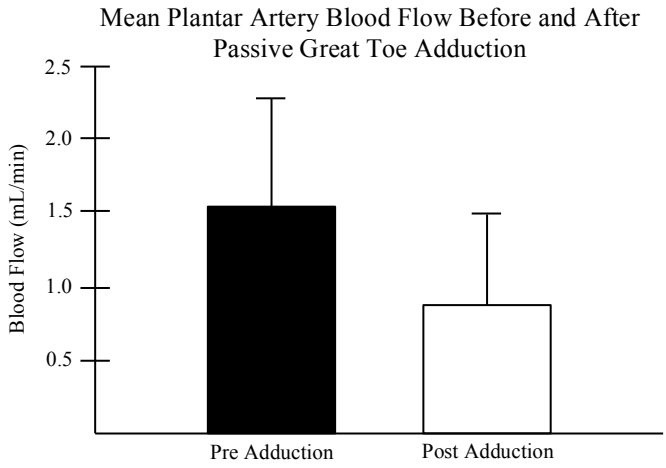

Effect of Plantar Fascia Stiffness upon First Metatarsophalangeal Joint Stress – A Biphasic Finite Element Study

[1, 2]Rajshree Hillstrom, [1]Oliver J Morgan, [2]Matt Koff, [2]Scott J Ellis, [2]Jonathan T Deland, and [2]Howard J Hillstrom
[1]Anglia Ruskin University; [2]Hospital for Special Surgery
Email of Presenting Author: Rajshree.Hillstrom@ anglia.ac.uk

Disclosures: Rajshree Hillstrom (Moximed), Oliver J Morgan (N), Matt Koff (N), Scott J. Ellis (Wright Medical), Jonathan T Deland (N), Howard J Hillstrom (Moximed, APOS, JAK Tool)

INTRODUCTION: The plantar fascia is considered an important architectural element for maintaining the height of the arch.[1] Excessive strain of this tissue promotes bony remodeling of the calcaneus (heel spur) and one of the most common pedal pathologies: plantar fasciitis. Prolonged stress will limit 1st metatarsophalangeal (MTP) dorsiflexion and may impact the magnitude and location of stress within the 1st MTP joint. Wright (1964) initially described the plantar fascia as a linearly elastic element with a 350MPa modulus.[2] This study aims to model the 1st MTP joint with viscoelastic representations of cartilage to estimate joint contact stress with the plantar fascia moduli at 200%, 100%, 50%, and 25% of nominal (350MPa).

METHODS: Three-dimensional (3D) subject-specific finite element (FE) models of the 1st MTP joint were created from MRI-datasets of a cadaveric first ray (metatarsal, proximal phalanx, sesamoids, and hallux), without OA, and were previously developed and compared with *in vitro* testing to provide experimental validation. Tissues were segmented in Mimics (Materialise, Belgium), assembled in CATIA (Dassault Systèmes, France), meshed in Abaqus (Dassault Systèmes, France), and loaded with axial force and bending moments in FEBIO (Utah, USA). Bones were modelled as rigid bodies for this quasi-static analysis. Cartilage was modeled as viscoelastic (E=10MPa, v=0.07, permeability=0.002). Fourteen ligaments (tension-only 'wires': E=260MPa) and the plantar fascia (E=87.5 MPa - 700 MPa, v=0.4) were also modelled. Vertical forces of were applied to the hallux and sesamoid bones, respectively, to simulate a quarter of physiological loading conditions experienced during gait (Hillstrom, 2013). A horizontal force was applied to the plantar fascia to achieve static equilibrium. The plantar fascia modulus was evaluated at 200%, 100%, 50%, 25% of the nominal value (E=350MPa)

RESULTS: Peak von Mises stress distributions on the proximal phalanx base cartilage surface (presented in Figure 1) for plantar fascia moduli of 700MPa, 350MPa, 175MPa, and 87.5MPa are 1.66 MPa, 1.67 MPa, 1.74 MPa and 1.90 MPa, respectively. The corresponding peak von Mises Stress at the cartilage-subchondral bone interface are 3.0 MPa, 3.0 MPa, 3.15 MPa and 3.44 MPa, respectively.

DISCUSSION: Arch height was inversely related to plantar fascia moduli.[1] This investigational team has recently demonstrated that peak von Mises stress increases by 15% when planatar fascia modulus is 25% of nominal. Taken together with the results of this study it is logical that Peak stress would increase with decreasing plantar fascia moduli.

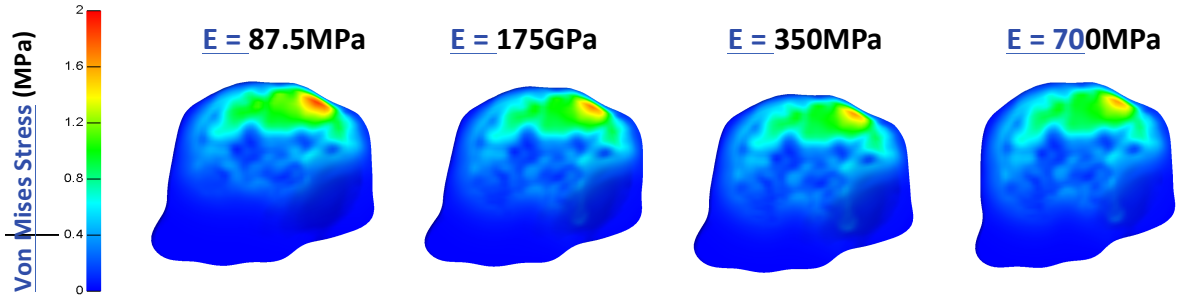

Figure 1: Effect of plantar fascia stiffness on first metatarsophalangeal joint von Mises stress

REFERENCES:

1. Tak-Man Cheung et al, Clinical Biomechanics 19, 2004
2. Wright, D., Rennels, D., 1964. J. Bone Joint Surg. Am. 46, 482–492.
3. Hillstrom et al, Gait & Posture, 2013

Cheilectomy and Moberg Osteotomy: A Biphasic Prediction of First Metatarsophalangeal Joint Stress

Oliver J. Morgan[1], Rajshree Hillstrom[1, 2], Matthew F. Koff[2], Scott J. Ellis[2], Jonathan T. Deland[2], Howard J Hillstrom[2]
[1]Anglia Ruskin University, England, UK, [2]Hospital for Special Surgery, NY, USA
Email of Presenting Author: oliver.morgan@anglia.ac.uk

Disclosures: Oliver J Morgan (N), Howard J Hillstrom (Moximed, Apos, Jak Tool), Matt Koff (N), Scott J. Ellis (Wright Medical), Jonathan T Deland (N), Rajshree Hillstrom (Moximed)

INTRODUCTION: First metatarsophalangeal (1st MTP) joint osteoarthritis (OA) is the most common degenerative joint disease in the foot (1). Cheilectomy combined with proximal phalangeal dorsiflexion (Moberg) osteotomy is a joint sparing procedure for mild to moderate disease. The purpose of combining a cheilectomy with a Moberg osteotomy is to shift the area of joint contact and thus, reduce edge-loading post-cheilectomy; however, 1st MTP joint contact mechanics after the preferential Moberg osteotomy wedge geometry (3 mm) is unknown. Therefore, the aim of this study was to predict 1st MTP joint loading following cheilectomy with a Moberg osteotomy titration of 3 mm using a biphasic finite element (FE) model of the first ray.

METHODS: A three-dimensional (3D) cadaver-specific FE model of a first ray was developed. The specimen was imaged using a 3T MRI-scanner (metatarsal, proximal phalanx, distal phalanx, sesamoids, plantar fascia, and cartilages), and was free from OA. Each tissue was segmented in Mimics (Materialise, Belgium), assembled in Catia V5 (Dassault Systèmes, France), meshed in Abaqus 6.14 (Dassault Systèmes, France), and simulated in FEBio 2.6.4 (University of Utah, USA). To reduce computational expense the bones and ground were assigned as rigid bodies. The material properties of cartilage (E=10MPa, v=0.07, perm=0.002), plantar fascia (E=350MPa, v=0.4), and ligaments (tension-only fiber models, E=260MPa) were used for the remaining soft-tissue structures. Dorsal metatarsal head geometry was reduced by approximately, 30% to simulate a cheilectomy, and the proximal phalanx modified with Moberg osteotomy titrated to 3 mm. The metatarsal bone was then rotated in a physiological manner to simulate a planus arch-alignment (10° metatarsal declination angle). Loading conditions were determined firstly, at a quarter scale of maximum force parameters reported beneath the metatarsal head (33 N) and hallux (34 N) for pes planus (2), and secondly, the resulting plantar fascia force (225 N) in order to achieve static equilibrium.

RESULTS: The computationally-predicted von Mises (MPa) distributions at the proximal phalanx cartilage surface for each simulation are shown in Fig 1. A cheilectomy and Moberg osteotomy titrated to 3 mm presented greater focal stress, as well as a more plantar distribution of cartilage loading for this specimen.

DISCUSSION: The analyses demonstrated a positive correlation between plantar shifting of joint contact and Moberg osteotomy titration as well as an increase in the magnitude of peak stress post-virtual surgery. There are several limitations with this experiment, 1) only one model was analyzed, 2) the material properties were not specimen-specific including an increased elastic modulus for cartilage and, 3) the plantar fascia force was assumed the same between each simulation and as such, may not reflect the concomitant changes to the plantar fascia load and likely, maximum force parameters following Moberg osteotomy.

SIGNIFICANCE/CLINICAL RELEVANCE: For this specimen, a Moberg osteotomy titration of 3 mm will plantarly load the cartilage. A larger dataset will be used in the future to better predict preferential loading of 1st MTP joint cartilage post-cheilectomy and Moberg Osteotomy.

REFERENCES:

1. van Saase, JL. *Annals Rheum Disease.* 1989.
2. Hillstrom et al.. *Gait & Posture.* 2013.

ACKNOWLEDGEMENTS: Hospital for Special Surgery Foot and Ankle Fund.

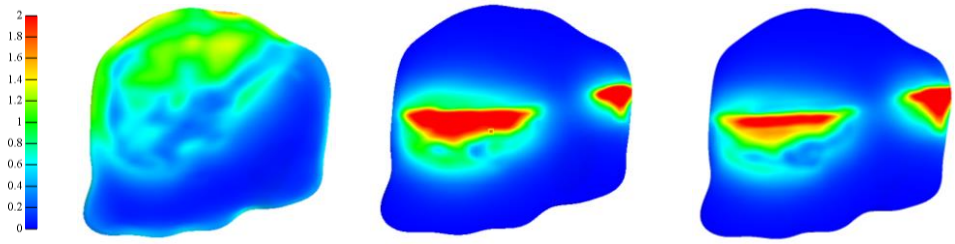

Figure 1. von Mises distributions in the proximal phalanx base cartilage (posterior view) from left to right: intact, cheilectomy and no osteotomy, and cheilectomy and 3 mm osteotomy.

Session 11-5

Evaluation of joint mobility around the cuneiform between hallux valgus and normal feet using 3D analysis system and weight-bearing CT.

Tadashi Kimura[1], Makoto Kubota[1], Hidekazu Hattori[1], Kazuhiko Minagawa[1], Naoki Suzuki[2], Asaki Hattori[2], Keishi Marumo[1]
[1]Department of Orthopaedic Surgery, The Jikei University School of Medicine, Tokyo, Japan,
[2]Institute for High Dimensional Medical Imaging, The Jikei University School of Medicine, Tokyo, Japan
Email of Presenting Author: tadashi-kimura@jikei.ac.jp

Disclosures: Tadashi Kimura (N), Makoto Kubota (N), Hidekazu Hattori (N), Kazuhiko Minagawa (N), Naoki Suzuki (N), Asaki Hattori (N), Keishi Marumo (N)

INTRODUCTION: An association has been reported between hallux valgus and hypermobility of the first ray, but hypermobility of the intercuneiform 1-2 joint was also suspected in some cases. However, dynamics of the intercuneiform 1-2 joint has seldom been investigated. This study used weightbearing computed tomography (CT) and a 3-dimensional (3D) analysis system to evaluate displacement of the intercuneiform 1-2 joint, intercuneiform 2-3 joint, and second cuneonavicular joint due to weightbearing in hallux valgus and normal feet.

METHODS: Patients were 11 women with hallux valgus (mean age, 56 years; mean hallux valgus angle, 43 degrees; mean first-second intermetatarsal angle, 22 degrees) and 11 women with normal feet (mean age, 57 years; mean hallux valgus angle, 14 degrees; mean first-second intermetatarsal angle, 9 degrees). Each patient was placed supine with the lower limbs extended, and CT was performed under nonweightbearing and weightbearing conditions (load equivalent to body weight)[1](Fig 1). 3D models reconstructed from CT images (Fig 2). Then, 3D analysis was performed to quantify the displacement of the middle cuneiform relative to the medial cuneiform and the displacement of the lateral cuneiform relative to the middle cuneiform and the displacement of the middle cuneiform relative to the navicular under nonweightbearing and weightbearing conditions. We compared data between the control group and the hallux valgus group.

RESULTS: Relative to the medial cuneiform, the middle cuneiform was displaced by 0.1 and 0.8 degrees due to dorsiflexion, 0.2 and 1.0 degrees due to inversion, and 0.7 and 0.7 degrees due to abduction in normal feet and feet with hallux valgus, respectively, with the latter having significantly greater dorsiflexion (P = .0067) and inversion (P = .0019) (Fig 3a). There was no significant intergroup difference at the intercuneiform 2-3 joint and second cuneonavicular joint (Fig 3b,3c).

DISCUSSION: We conducted a detailed three-dimensional evaluation of cuneiform mobility, which has been difficult to evaluate by other methods such as plain radiography. The findings of this study showed that relative to the medial cuneiform, the middle cuneiform was significantly displaced due to dorsiflexion and inversion under weightbearing conditions in patients with hallux valgus, suggesting that hallux valgus also involves hypermobility at the intercuneiform 1-2 joint.

SIGNIFICANCE: It may be possible to further improve postoperative outcomes of the modified Lapidus procedure through arthrodesis of the intercuneiform 1-2 joint, especially in patients with severe hypermobility of this joint.

REFERENCES:

1. Kimura T, Kubota M, et al. Evaluation of first ray mobility in patients with hallux valgus using weightbearing CT and a 3D analysis system: a comparison with normal feet. J Bone Joint Surg Am.2017; 99: 247-255.

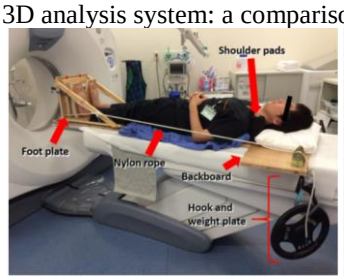

Fig 1

Fig 2

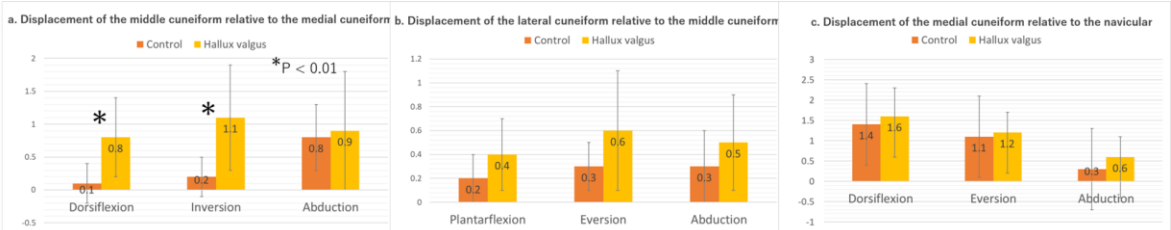

Fig 3

Comparing First Metatarsophalangeal Joint Flexibility Measurements in Hallux Rigidus Patients Pre- and Post-Cheilectomy Using a Novel Flexibility Device

Lauren G. Volpert[1], Elizabeth A. Cody, MD[1], Jensen K. Henry, MD[1], Andrew P. Kraszewski PhD[1], Howard J. Hillstrom, PhD[1], Scott J. Ellis, MD[1]
[1]Hospital for Special Surgery, New York, NY
Email of Presenting Author: Volpertl@hss.edu

Disclosures: No disclosures.

INTRODUCTION: Few authors have studied flexibility of the first metatarsophalangeal joint (MTPJ), which has been shown to be decreased in patients with hallux rigidus (HR). The most widely used classification system for HR, which uses only range of motion and radiographic findings to guide treatment, may give an incomplete picture of the involved pathology. In a previous study (Phase I), we described a method to measure first MTPJ flexibility using a custom jig and tested it in both HR patients and controls, with excellent intra- and interrater reliability. In this study (Phase II), our objective was to measure first MTPJ flexibility of the same HR patients post-cheilectomy to determine the effect of surgery on joint flexibility.

METHODS: This study was approved by the IRB at the authors' institution and informed consent was obtained from all enrolled patients. Thirteen hallux rigidus patients from Phase I were contacted to participate. Ten patients were enrolled and underwent MTPJ flexibility testing. The operated first MTPJ was manually loaded to maximum dorsiflexion and then back to neutral cyclically five times for each trial. Prior to each trial, the joint was cyclically loaded ten times to pre-condition the soft tissues. Testing was performed both sitting and standing. Early and late flexibility [º/lb-inch], laxity angle [º], laxity torque [lb-inch], torque angle [º], and maximum dorsiflexion angle [º] were compared between the preoperative and postoperative datasets for six patients using paired-samples 1-tailed t-tests with significance set at alpha = .05. Only data for six patients were used due to a technical problem affecting four datasets.

RESULTS: Late flexibility ($P < 0.022$), maximum dorsiflexion ($P < 0.010$), and laxity angle ($P < 0.006$) were significantly improved postoperatively in the seated position (Table). Early flexibility and laxity torque did not differ significantly between the pre- and postoperative conditions in the seated position. No measurements were significantly different in the standing position.

DISCUSSION: Measures of flexibility were significantly improved after cheilectomy. This finding likely reflects improved function of the MTPJ after removal of dorsal impingement, but could also be due to the effects of releasing the joint capsule. The reason why improvement was noted only in the seated position is not clear, but may be related to increased soft tissue tension in the standing position. Future studies will be needed to confirm these results with more patients and to determine the effect of different procedures. In addition, it will be helpful to correlate other outcome measures with measures of laxity.

SIGNIFICANCE: This is the first study to demonstrate improvement in first MTPJ flexibility after cheilectomy. These measures may help surgeons better gauge function compared to traditional radiographic and motion parameters.

Table: *P* values for Comparisons between Pre- and Post-Operative Patients

	Parameter	Pre-Op	Post-Op	Delta	p-value
Seated	Early Flexibility	0.52 (0.24)	0.71 (0.61)	0.19 (0.61)	0.240
	Late Flexibility	0.18 (0.09)	0.10 (0.04)	0.08 (0.07)	**0.022**
	Max Dorsiflexion	32 (11)	51 (16)	19 (14)	**0.010**
	Laxity Angle	20 (9)	33 (10)	13 (8)	**0.006**
	Laxity Torque	72 (24)	94 (55)	22 (44)	0.136
Standing	Early Flexibility	0.16 (0.09)	0.16 (0.13)	0.00 (0.13)	0.466
	Late Flexibility	0.14 (0.07)	0.11 (0.04)	0.03 (0.07)	0.180
	Max Dorsiflexion	21 (10)	33 (18)	11 (15)	0.062
	Laxity Angle	13 (6)	24 (16)	11 (15)	0.074
	Laxity Torque	148 (36)	242 (161)	93 (165)	0.112

$P < 0.05$ are bolded.

Figure: Flexibility Device